

Morphological Evaluation and Inter-hemispheric Differences of Human Sylvian Sulcus: A Cadaveric Study

Shilpa N Gosavi¹

¹Department of Anatomy, Bharati Vidyapeeth (Deemed to be University), Medical College, Pune, Maharashtra, India

Corresponding Author

Shilpa N Gosavi

E-mail ID: shilpa.gosavi@bharativedyapeeth.edu

Submission: 15.12.2022

Acceptance: 09.03.2023

Publication: 31.03.2023

https://www.doi.org/10.56136/BVMJ/2022_00110



Abstract

Background: The current literature specifies variations in the morphology of the lateral sulcus in the human brain, and it is highly confined to the point of its posterior termination. The present study was conducted to evaluate morphometric characteristics of lateral sulcus as well as to find out associated interhemispheric differences among adult brain samples.

Methodology: A cross-sectional study was carried out at the Department of Anatomy of one of the medical colleges in Pune city of Maharashtra. In the study, 54 formalin-fixed intact adult brains, irrespective of gender, were examined. The lateral sulcus was inspected for each segment, surface, and termination from the given samples. The data was entered into Microsoft Office Excel Sheet. The data analysis was done using Statistical Package for Social Sciences (SPSS) version 25 software. **Results:** The most frequently occurred termination types, viz. oblique and straight. The U-shaped configuration was observed to be the commonest pattern. The diagonal sulcus was noted in 32 (59.25%) hemispheres, while the triangularis sulcus was identified in 45 (83.33%) hemispheres. The mean of the total length of the lateral sulcus on the left side was greater than on the right side. The left lateral sulcus was significantly longer than the right, and both were positively correlated. **Conclusion:** The findings of present study conform to the literature regarding the morphology of lateral sulcus and associated inter-hemispheric differences related to it.

Key words: Branching, Cerebral Hemispheres, Lateral Sulcus, Morphology, Sylvian Fissure, Triangularis sulcus, Diagonal sulcus

Introduction

Anatomical brain asymmetries are understated and studied in a limited manner among the human population⁽¹⁾. Among all the animals, humans show the most asymmetric brains⁽¹⁾. The two cerebral hemispheres are the biggest foremost portions of the brain. Each hemisphere is composed of an intricate cortex with an infolding mass of white matter, which partially encircles the basal ganglia⁽²⁾.

Each hemisphere shows three major surfaces, viz. medial, basal, and superolateral, with lateral and central sulcus on the later surface⁽³⁻⁶⁾. Sylvian Fissure (SF), also known as the lateral sulcus, is one of the first sulci to form on the cerebrum. It is situated on the lateral surface of a hemisphere and divides the frontal and parietal lobes from the temporal lobe inferiorly⁽³⁾. The lateral sulcus divides ventrally at the Sylvian point and splits into an anterior, inferior, and ascending limb. The anterior limb separates pars orbitalis below from pars triangularis above, whereas the ascending ramus divides the pars triangularis anteriorly from pars opercularis posteriorly⁽³⁻⁶⁾. The posterior limb continues dorsally from the Sylvian point⁽⁶⁾.

The existing literature indicates variations in the anatomy of the lateral sulcus in the human brain, and it is highly confined to the point of its posterior termination^(7,8). Broca's motor speech area and Wernicke's speech association area lies in the

vicinity of the lateral sulcus. It is believed that interhemispheric asymmetry of the lateral sulcus and perisylvian cortex may be the basis for hemispheric dominance for language⁽⁷⁻⁹⁾. The predominant sulci contours and rami of the lateral sulcus are commonly used to delineate the pars opercularis and pars triangularis from the adjacent cortex and are found to be useful in various operative neurosurgeries⁽⁷⁻⁹⁾. However, an assessment of inter-individual variations in a larger sample population has indicated significant diversity in the morphology of these sulci and rami, as mentioned in a few studies⁽⁷⁻¹⁰⁾.

The present study was conducted to assess morphometric features of the lateral sulcus as well as to gauge associated interhemispheric differences among adult brain specimens.

Material and Methods

A cross-sectional study was designed and conducted in the Department of Anatomy of one of the tertiary health care institutes in the Pune District of Maharashtra. The study was conducted over a period of two years from 2018 to 2020.

Participants and inclusion/exclusion criteria

Cadaveric bilateral cerebral hemispheres of adults with no gross damage or deformity were included. Infant and adolescent brains and adult hemispheres with any gross morphological variation were excluded from the study.

Sample size estimation and sampling method

In the study, 54 formalin-fixed adult cerebral hemispheres, irrespective of gender, were examined. A statistical method was not applied to calculate the sample size, however the sample size was decided depending on the availability of the specimen in the department.

Variables and operational definitions

From the selected samples, the lateral sulcus was examined for each segment and its termination. The lateral sulcus and Sylvian point with its posterior limb, anterior limb, and ascending limb were defined. The termination of the lateral sulcus was noted for its bifurcation. The length of the posterior limb of the lateral sulcus, anterior ascending limb, and anterior horizontal limb were considered separately for the left and right sides. All measurements were taken with the help of Black silk suture material positioned on the surface. Either ends of the suture material were held with artery forceps to ensure accuracy.

The branching pattern of the anterior limb and ascending limb was noted. The presence of diagonal sulcus in pars opercularis and triangularis sulcus in pars triangularis was noted.

Data collection tools

All the observations were documented in the preformed 'observation sheet'.

Data analysis

The data was entered into Microsoft Office Excel Sheet. The data analysis was done using Statistical Package for Social Sciences (SPSS) version 25 software. All continuous variables were computed as mean with standard deviations. Statistical differences were tabulated with Student's t-test. A p-value less than 0.05 was considered statistically significant.

Results

Table 1 depicts various termination types of the posterior limb of the lateral sulcus in the present study. The most frequently occurring termination type was oblique (38.88%) and straight (29.62%).

Table 1: Termination Types of Lateral Sulcus (n=54)

| Termination Type | Number (%) |
|----------------------|------------|
| Oblique | 21 (38.88) |
| Straight | 16 (29.62) |
| Superior limb longer | 14 (25.92) |
| Inferior limb longer | 02 (3.70) |
| Equal | 01 (1.85) |

In the current study, anterior ascending and anterior horizontal ramus were seen in 52 (96.29%) hemispheres. The branching pattern of anterior ascending and anterior horizontal rami of the lateral sulcus was U-shaped in 24 (44.44%), V-shaped in 23 (42.59%), and common stem in 7 (12.96%) studied samples. Thus, the branching pattern of the anterior ascending and anterior horizontal rami from the anterior Sylvian point, which was a U-shaped configuration, was observed to be the most common pattern in the present study. (Figure 1)

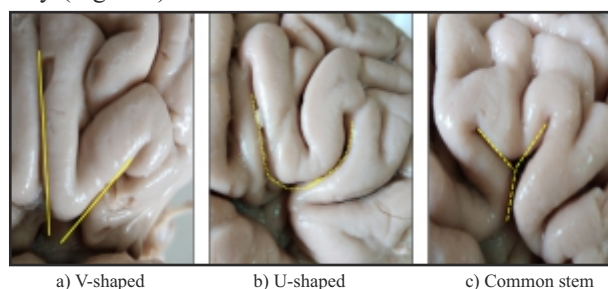


Figure 1: Showing branching pattern of anterior horizontal and anterior ascending ramus

The mean measurements of different limbs of the lateral sulcus were noted. The mean length of the posterior limb was 70.03 mm, whereas the mean length of the Anterior Horizontal Ramus (AHR) and Anterior Ascending Ramus (AAR) was 12.83 mm and 16.23 mm, respectively. The mean length from the Anterior Sylvian Point (ASP) to the Precentral Sulcus (PCS) was 12.62 mm, and from ASP to the Inferior Rolandic point (IRP), was 26.89 mm.

In this study, overall, the mean of the total length of the lateral sulcus on the left side was greater than on the right side. The mean of the length of AHR on the left side ($13.02 \text{ mm} \pm 6.04$) was more than the right side ($12.63 \text{ mm} \pm 4.28$). The mean value of the left AAR ($16.84 \text{ mm} \pm 10.88$) was larger than the mean value of the right AAR ($15.69 \text{ mm} \pm 5.13$). But the difference in these was not significant statistically (for AHR $p = 0.79$, for AAR $p = 0.87$). The mean value of the posterior limb of the lateral sulcus was higher on the left side than on the right side (Left - $71.22 \text{ mm} \pm 7.97$, Right - $68.89 \text{ mm} \pm 10.4$, $p = 0.37$).

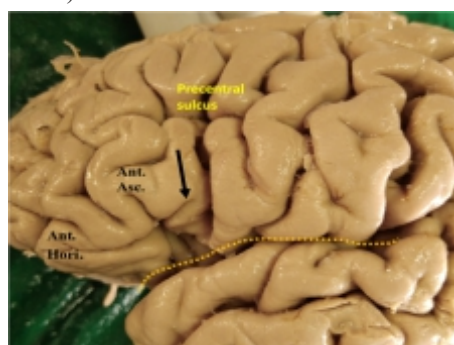


Figure 2: Diagonal sulcus (black arrow) in pars opercularis of Left Cerebral hemisphere between Inferior part of precentral sulcus and Anterior ascending ramus (Ant. asc.). Dotted line indicates Lateral sulcus

The diagonal sulcus (Figure 2) was noted in 32 (59.25%) hemispheres, while the triangularis sulcus was identified in 45 (83.33%) hemispheres (Figure 3). However, the presence of the triangularis sulcus was not dependent on the side ($p > 0.05$). On the contrary, the diagonal sulcus was frequently present on the left side ($p < 0.05$).

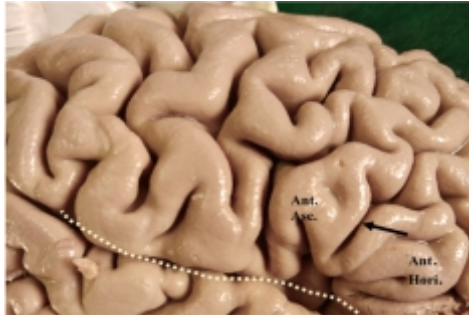

Figure 3: Triangularis sulcus (black arrow) in right Cerebral hemisphere in pars triangularis between Anterior horizontal (Ant. Hori.) and Anterior ascending ramus (Ant. Asc.). Dotted line indicates Lateral sulcus

Discussion

The lateral sulcus is considered as an essential indicator of the leftward cerebral asymmetry existing in language reception areas of the brain. Several research articles on the lengths of the human lateral sulcus have reported the left to be longer than the right⁽⁸⁾, which was supported by the current study.

In our study, AAR and AHR were present in the majority (96.29%) of hemispheres. Out of three identified configurations (U, V, and common stem) of AAR and AHR, the commonest observed pattern in the study was the U and V shaped, both accounting for almost 88%. In other autopsy studies carried out by Sudakshina et al.⁽⁸⁾ and Idowu et al.⁽¹¹⁾, AAR and AHR were seen in all cerebral hemispheres. However, both studies reported U and V-shaped branching patterns in 78% and 70% of hemispheres. Conversely, Ayberket et al.⁽¹²⁾ revealed a different finding in which the branching pattern of the common stem was noted in 39.3% of hemispheres, and a U-V-shaped configuration was reported only in 28.6% of hemispheres.

In the context of diagonal and triangularis sulcus, they were identified almost in 60% and 84% of hemispheres in the current study. Comparative findings were reported in the study conducted by Idowu et al.⁽¹¹⁾, where the triangularis sulcus was noted in 79% of hemispheres, and the diagonal sulcus was seen only in 42% of hemispheres.

Several morphometric studies were conducted to assess laterality and sexual dimorphism pertaining to the lateral sulcus^(13,14). Asymmetries of the lateral sulcus were documented, with a predominant leftward asymmetry steadily reported in multiple post-mortem studies. Gender-specific differences have also been reported with reduced asymmetries in females relative to males^(15,16). It reiterates the need to implement extensive gender-based research to bridge

knowledge gaps in this area. One of the major limitations of the current study was that it could not emphasize gender-specific variations in the morphology of the lateral sulcus.

The cerebral sulci are considered vital landmarks to select surgical passageway to access the deeply situated parts of the brain^(11,17). The lateral sulcus or Sylvian fissure is a commonly used surgical corridor and is of substantial significance in clinical neurology and intraoperative neurosurgeries. The surgeon's knowledge of the structure and a better awareness of the range of variations in the morphology of the lateral sulcus and its adjacent structures are highly crucial to interpret functional imaging studies as well as during intraoperative dissection procedures^(17,18). The published literature shows that knowledge of variations in the morphology of lateral sulcus assists neurovascular surgeons in training⁽¹⁹⁾. Several postoperative complications, like the development of ischemic lesions or brain edema, are associated with anatomical variations of the lateral sulcus⁽¹⁹⁾. Procedure-linked morbidity can be reduced considerably with preoperative knowledge of lateral sulcus variations and helps to adopt a suitable surgical approach. The emerging results from the present study would be beneficial to strengthen the database regarding the morphology of lateral sulcus and inter-hemispheric differences related to it.

One of the major limitations of the study was that it could not attempt to establish the relation between the structural and functional asymmetries between both cerebral hemispheres with reference to language and speech lateralization. Similar studies should be strongly encouraged to generate data that can reinforce the existing literature. A statistical estimation of sample size was another limitation of the study.

Conclusion

The left lateral sulcus was significantly longer than the right, and both were positively correlated. The anterior, posterior, and ascending limbs of the lateral sulcus were longer on the left side, and U-shaped branching was the commonest configuration bilaterally. The presence of the triangularis sulci is frequently encountered compared to the diagonal sulci. The findings of present study conforms to the literature regarding the morphology of lateral sulcus and inter-hemispheric differences related to it. With the preoperative knowledge of lateral sulcus variations, the procedure linked morbidity will reduce considerably and it will also help to adopt suitable surgical approach. The emerged results from the present study would be beneficial to strengthen the database regarding morphology of lateral sulcus and inter-hemispheric differences related to it.

Conflict of Interest: Nil

Source of Support: Nil

Copyright © 2023 Bharati Vidyapeeth Medical Journal (BVMJ). This is an open access article, it is free for all to read, download, copy, distribute, adapt and permitted to reuse under Creative Commons Attribution Non Commercial-ShareAlike: CC BY-NC-SABY 4.0 license.

ORCID

Shilpa N Gosavi  0000-0003-1573-0105

References

- Groen MA, Whitehouse AJ, Badcock NA, Bishop DV. Does cerebral lateralization develop? A study using functional transcranial Doppler ultrasound assessing lateralization for language production and visuospatial memory. *Brain Behav.* 2012 May;2(3):256-69.
- Patra A, Singla RK, Chaudhary P, Malhotra V. Morphometric Analysis of the Corpus Callosum Using Cadaveric Brain: An Anatomical Study. *Asian J Neurosurg.* 2020 Jun;15(02):322-7.
- Wang Y, Xu F, Zhou W, Hou L, Tang Y, Liu S, et al. Morphological and hemispheric and sex differences of the anterior ascending ramus and the horizontal ascending ramus of the lateral sulcus. *Brain StructFunct.* 2022 Jul;227(6):1949–61.
- Xu M, Baldauf D, Chang CQ, Desimone R, Tan LH. Distinct distributed patterns of neural activity are associated with two languages in the bilingual brain. *SciAdv.* 2017 Jul 12;3(7):1-9. e1603309.
- Westphal AJ, Reggente N, Ito KL, Rissman J. Shared and distinct contributions of rostrolateral prefrontal cortex to analogical reasoning and episodic memory retrieval. *Hum Brain Mapp.* 2016 Mar;37(3):896–912.
- Tang Y, Zhao L, Lou Y, et al. Brain structure differences between Chinese and Caucasian cohorts: a comprehensive morphometric study. *Hum Brain Mapp.* 2018 May;39(5):2147–55.
- Meybodi AT, Moreira LB, Gandhi S, Preul MC, Lawton MT. Sylvian fissure splitting revisited: Applied arachnoidal anatomy and proposition of a live practice model. *J ClinNeurosci.* 2019 Mar 1;61:235-242.
- Chakrabarti S, Vijayalakshmi S. Interhemispheric Variation of Sylvian Fissure: A Cadaveric Brain Study. *IntJ Anat Res.* 2015 Jun;3(2):1143-48.
- Narr KL, Bilder RM, Luders E, et al. Asymmetries of cortical shape: Effects of handedness, sex and schizophrenia. *Neuroimage.* 2007 Feb 1;34(3):939-48.
- Gonul Y, Songur A, Qzun I, et al. Morphometry, asymmetry and variations of cerebral sulci on superolateral surface of cerebrum in autopsy cases. *SurgRadiolAnat.* 2014 Sep;36:651-61.
- Idowu OE, Soyemi S, Atobatele K. Morphometry, asymmetry and variations of the sylvian fissure and sulci bordering and within the pars triangularis and pars opercularis An autopsy study. *JClinDiagn Res.* 2014 Nov;8(11):11-16.
- Ayberk G, Yagli OE, Comert A, et al. Anatomical relationship between the anterior Sylvian point and the Pars Triangularis. *ClinAnat.* 2012 May;25(4):429–36.
- Sawada K, Horiuchi-Hirose M, Saito S, Aoki I. MRI-based morphometric characterizations of sexual dimorphism of the cerebrum of ferrets (*Mustela putorius*). *Neuroimage.* 2013 Dec 1;83:294-306.
- Amol AS, Kushalini KA. Morphometry of Sylvian fissure among Maharashtrian population. *Natl J ClinAnat.* 2021 Apr 1;10(2):61-65.
- Foundas AL, Leonard CM, Gilmore RL, Fennell EB, Heilman KM. Pars triangularis asymmetry and language dominance. *Proc Natl AcadSci USA.* 1996 Jan 23;93(2):719-22.
- Foundas AL, Faulhaber JR, Kulynych JJ, Browning CA, Weinberger DR. Hemispheric and sex linked differences in Sylvian fissure morphology: a quantitative approach using volumetric magnetic resonance imaging. *Neuropsychiatry NeuropsycholBehavNeurol.* 1999 Jan 1;12(1):1-10.
- Im K, Jo HJ, Evans AC, Kim SI, Lee JM. Spatial Distribution of Deep Sulcal Landmarks and Hemispherical Asymmetry on the Cortical Surface. *CerebralCortex.* 2010 Mar 1;20(3):602–611.
- Keller SS, Highley JR, Garcia-Finana M, Sluming V, Rezaie R, Roberts N. Sulcal variability, stereological measurement and asymmetry of Broca's area on MR images. *Journal ofAnatomy.* 2007 Oct;211(4):534-55.
- Ngando HM, Maslehaty H, Schreiber L, Blaeser K, Scholz M, Petridis AK. Anatomical configuration of the Sylvian fissure and its influence on outcome after pterional approach for microsurgical aneurysm clipping. *SurgNeurolInt.* 2013 Sep;4:129-32.